




Feline  
Pyoderma: do  
allergic cats  
need  
antibiotics?

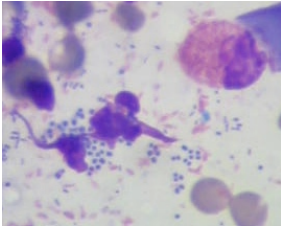

Brett Wildermuth  
DVM, BS (USA)  
Diplomate ACVD, ECVD

 TIERDERMATOLOGIE  
DR. WILDERMUTH

 TIERDERMATOLOGIE  
DR. WILDERMUTH

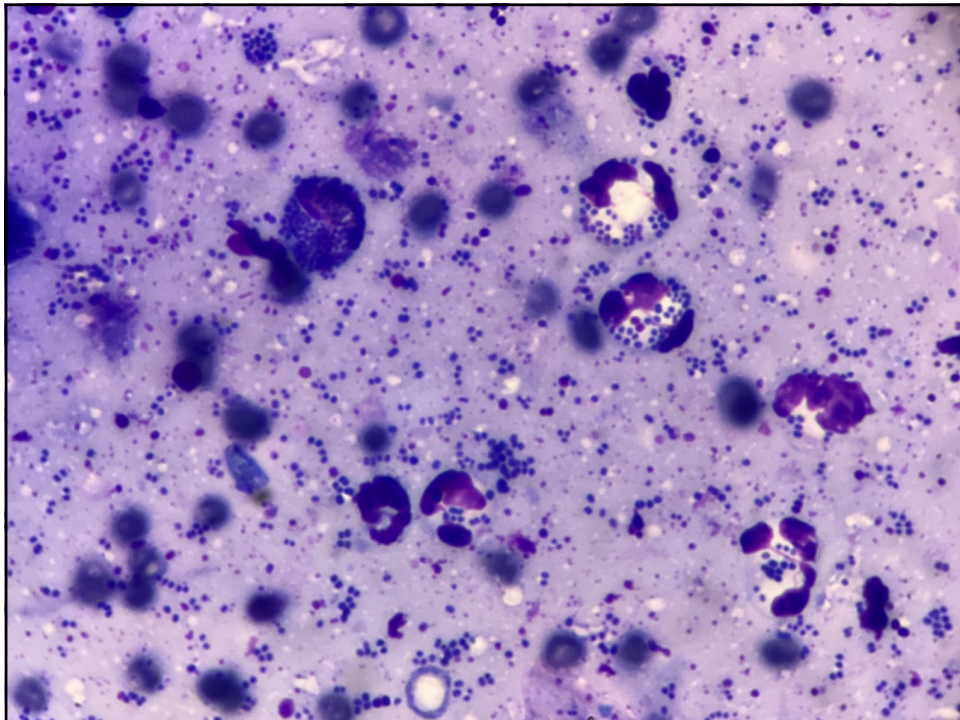
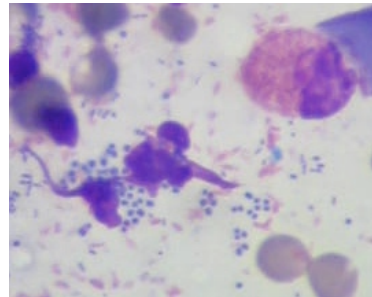
## Feline Pyoderma Overview

- Less common than the dog?
  - Under diagnosed?
- Secondary infection/overgrowth (dysbiosis) of opportunistic Staphylococci
  - Allergy is common
- Superficial >> deep

## Pyoderma: Diagnosis

- Cytology:
  - No totally official definition of pyoderma via cytology:
    - Strict: bacterial phagocytosis by neutrophils
    - My opinion: (Wildermuth): Bacteria & Neutrophils both present, even without phagocytosis



## Feline Pyoderma: Prevalence Lit.

- Feline dermatology at Cornell University: 1,407 cases (1988–2003). D.Scott, W. Miller (J Fel Med Surg, 2012)
  - **Pyoderma: 8.4%**, most allergic dermatitis
- Feline superficial pyoderma: a retrospective study of 52 cases (2001-2011). Yu HW, Vogelnest LJ. Vet Dermatol.
  - Prevalance: **Pyoderma 20%** all cases in the practice
    - Of those 60% allergic; 19% allergy suspected

## Feline Pyoderma Therapy: Lit.

- Differential diagnosis of feline miliary dermatitis. K. Kwochka (CVT IX, 1986)
  - 2/4 cases with miliary dermatitis -> Antibiotic cured
- Pyoderma in 5 cats, S.White (JAAHA, 1991)
  - 5 Cats -> antibiotic responsive lesions
- Feline pyoderma therapy. B.Wildermuth, C. Griffin, W Rosenkrantz (Clin Tech Small Anim Pract, 2006)
  - 3 cats: Indolent Ulcer, multiple eosinophilic plaques, deep Pyoderma/Panniculitis (Pseudomonas) – all healed with antibiotic

## Feline Pyoderma: Therapie Lit.

- Response of feline eosinophilic plaques and lip ulcers to amoxicillin trihydrate-clavulanate potassium therapy: a randomized, double-blind placebo-controlled prospective study.  
B.Wildermuth (Vet Derm, 2012)
  - n = 16; **All** lesions were infected - Cytology
  - Much fewer bacteria after Amoxiclav- stat. relevant
    - Plaques n= 9: 4 Amoxiclav: **much smaller**- stat. relevant
    - Lip Ulcers n= 8: 4 Amoxiclav: smaller – but not stat. rel.





## Feline Atopic Syndrome (FAS)

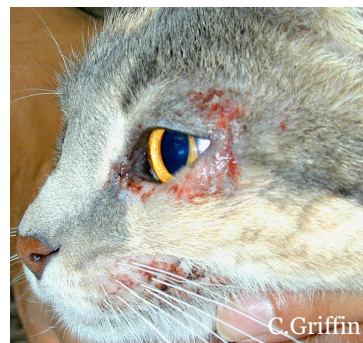ICADA

International Committee on  
Allergic Diseases of Animals

*Vet Dermatol* 2021; **32**: 26–e6

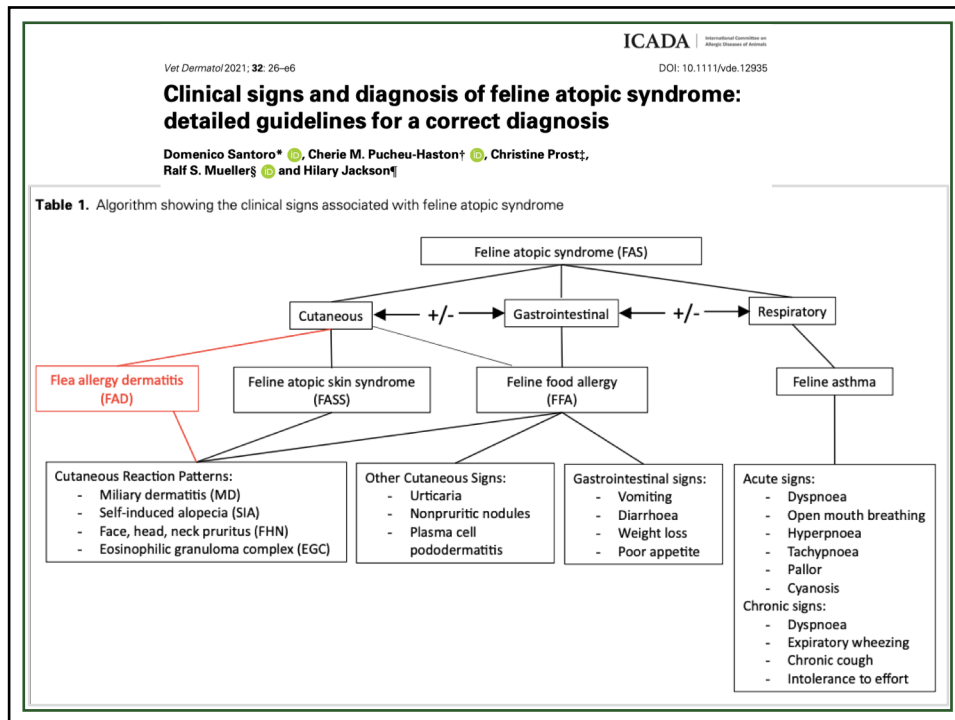
### Clinical signs and diagnosis of feline atopic syndrome: detailed guidelines for a correct diagnosis

Domenico Santoro\* , Cherie M. Pucheu-Haston† , Christine Prost‡, Ralf S. Mueller§  and Hilary Jackson¶ 



C. Griffin





TIERDERMATOLOGIE  
DR. WILDERMUTH

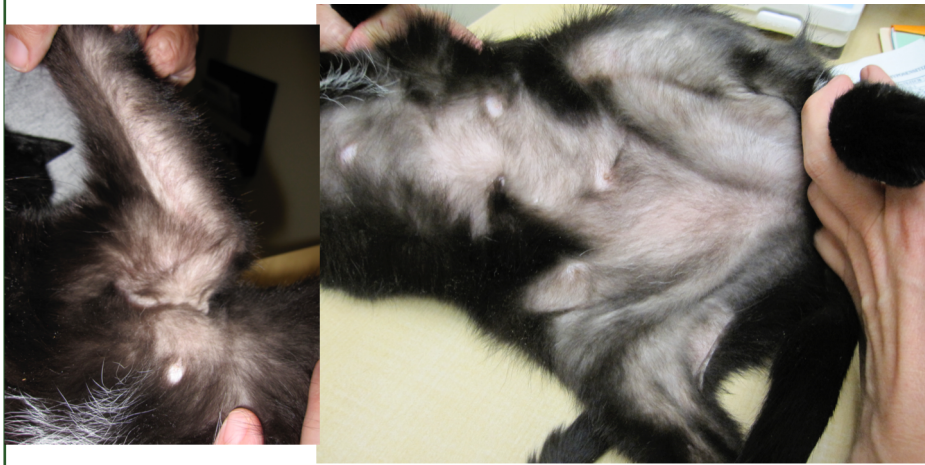
## 1. Miliary Dermatitis

W. Rosenkrantz

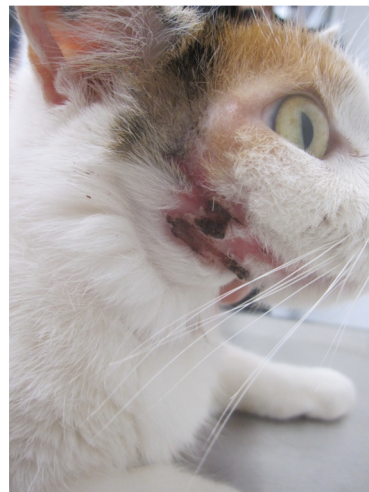
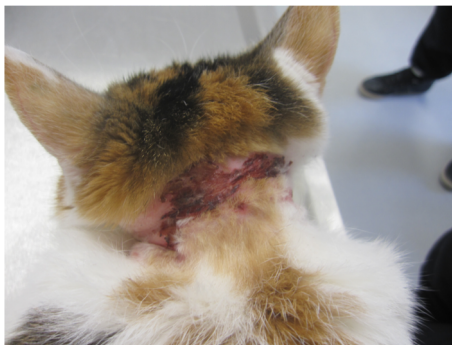K. Kwochka (CVT IX, 1986)  
2/4 miliary Dermatitis:  
Pyoderma

Yu HW, Vogelnest LJ. Feline superficial pyoderma: 15/52 cases (29%)

## 2. Self-induced Alopecia

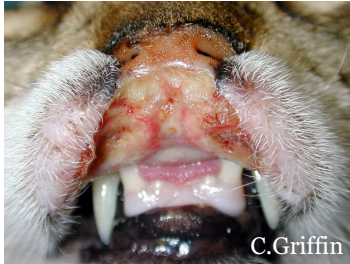

## 3. Face, Head, Neck, Pruritus

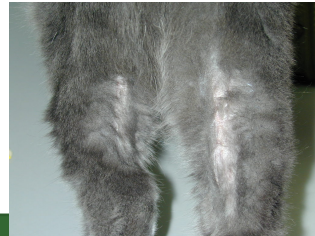
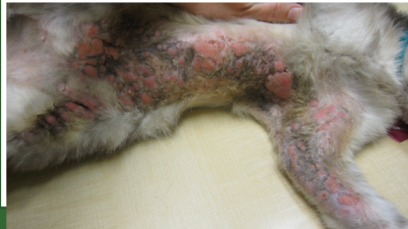
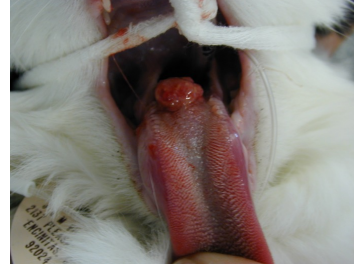Yu HW, Vogelnest LJ. Feline superficial  
pyoderma:  
Excoriation: 12/52 (23%)  
Ulceration: 14/52 (27%)

## 4. Eosinophilic Granuloma Complex

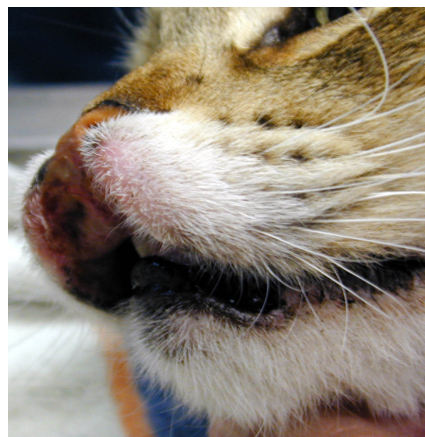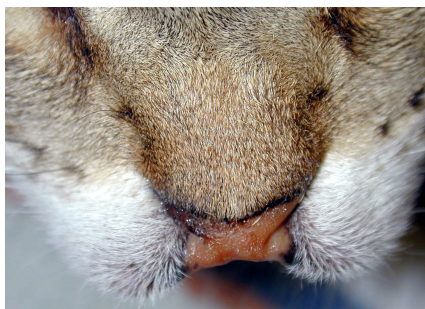


C.Griffin



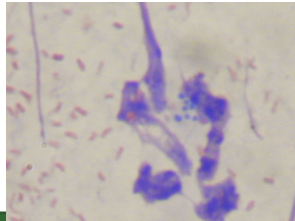
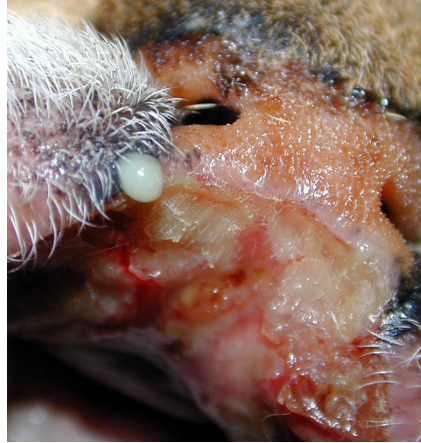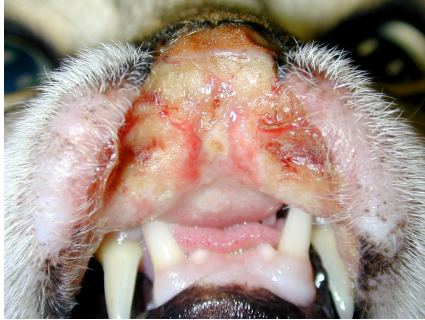## “Efram”

Feline pyoderma therapy. B.Wildermuth,  
**C. Griffin**, W Rosenkrantz (Clin Tech Small  
Anim Pract, 2006)  
Cat: Indolent Ulcer,

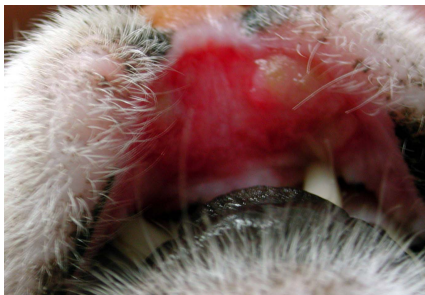




“Efram”

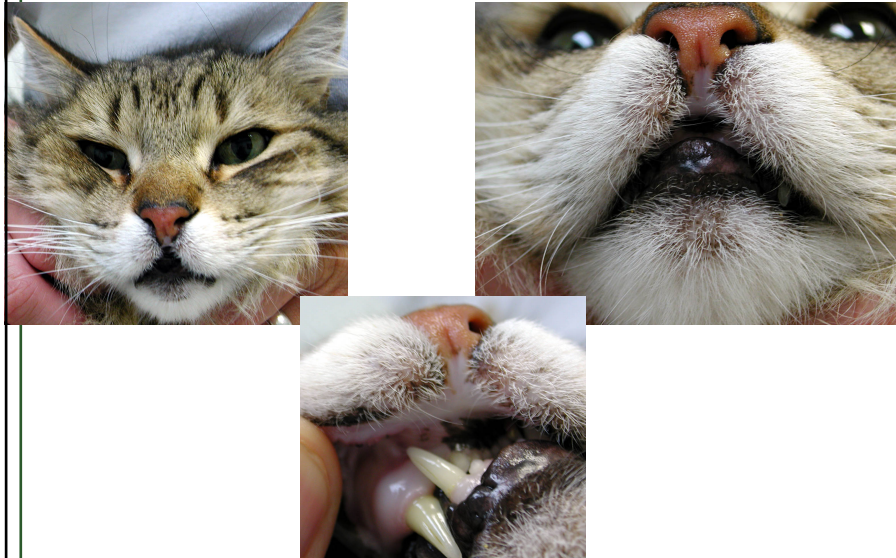

“Efram” after 3 weeks of antibiotics





## 7 weeks of antibiotics -> Photos 3.5 months later

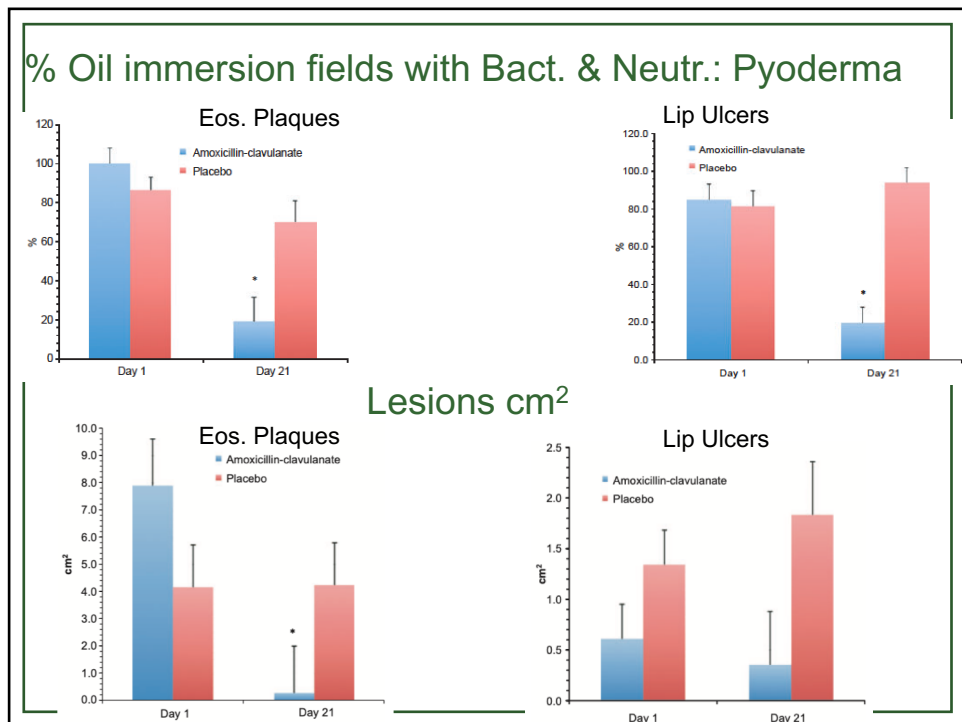
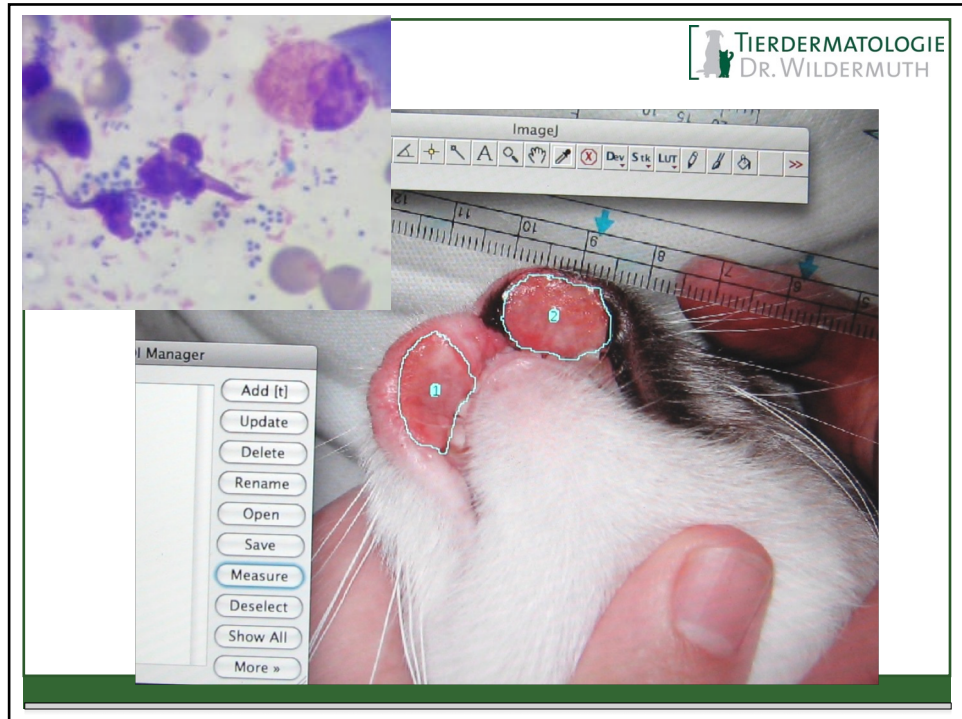

### Response of feline eosinophilic plaques and lip ulcers to amoxicillin trihydrate–clavulanate potassium therapy: a randomized, double-blind placebo-controlled prospective study

Veterinary Dermatology

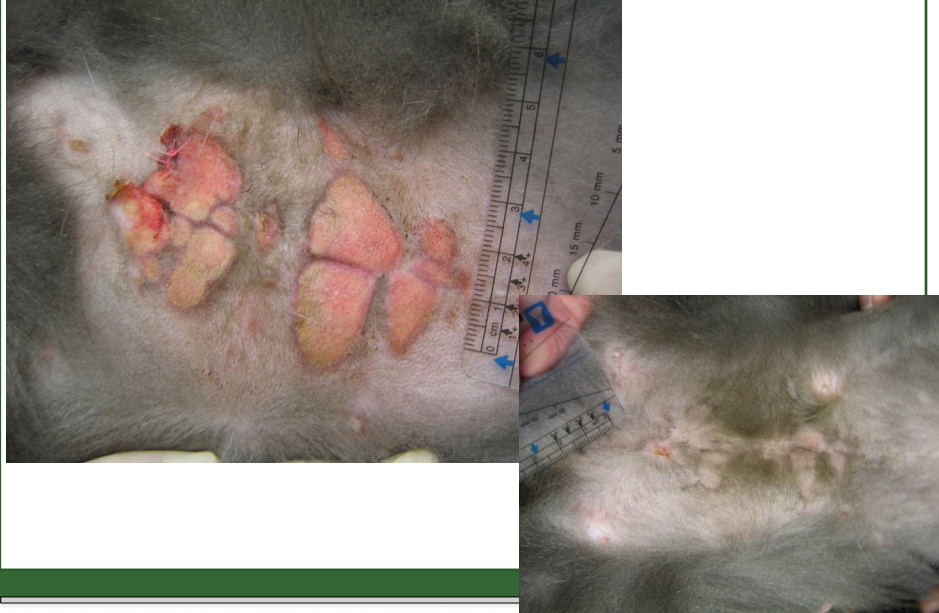Brett E. Wildermuth\*, Craig E. Griffin\* and Wayne S. Rosenkrantz†

- 16 Cats (eosinophilic Plaques: 9; Lip Ulcer: 8)
- Amoxiclav 13.8mg/kg or Placebo 2x tgl. over 3 Wk.
- Before & after therapy
  - photographed lesions & measured area in cm<sup>2</sup>
- Cytology before & after tx, C &S, Biopsy
  - Plaques with Amoxiclav 96,2% smaller\*, Placebo: größer
  - Lip Ulcers with Clavamox 42,6% smaller, Placebo: größer – but not stat. relevant



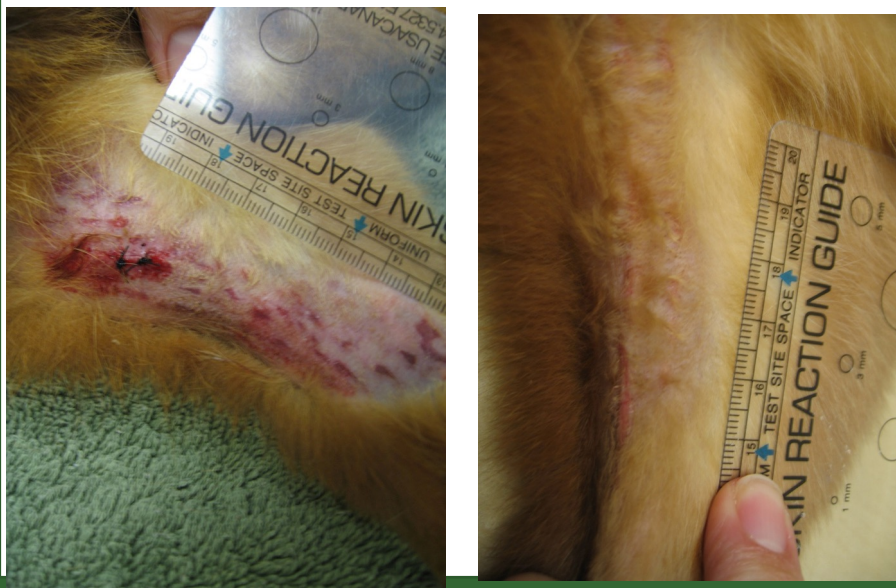## “Wilbur” Amoxiclav

TIERDERMATOLOGIE  
DR. WILDERMUTH



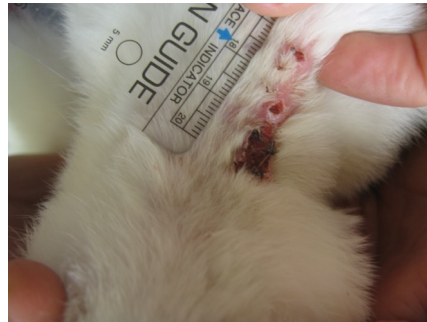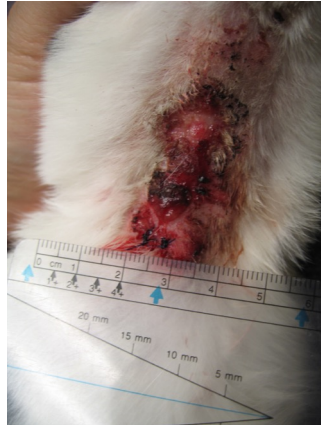## “Fruitloop” Amoxiclav

TIERDERMATOLOGIE  
DR. WILDERMUTH

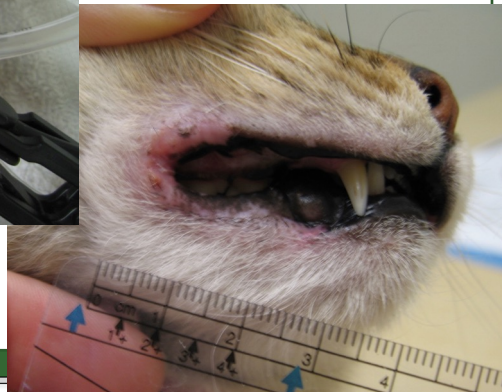
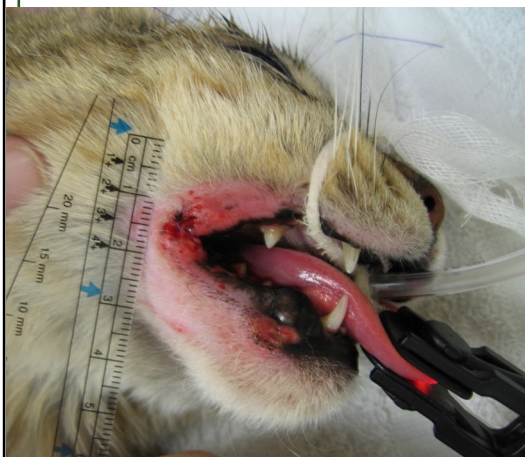



## “Tiny” Amoxiclav

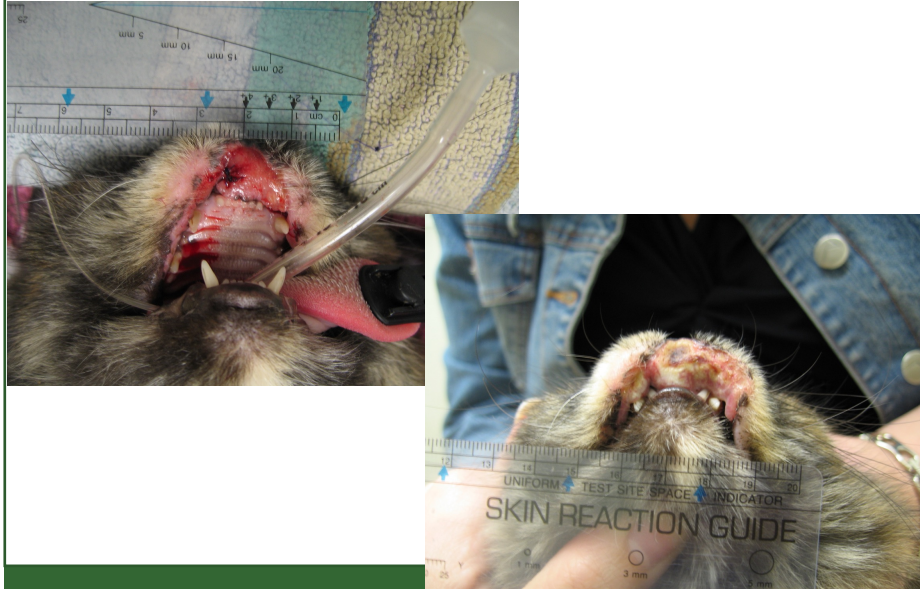

## “Natasha” Amoxiclav





## „Ethyl“ Plazebo



## Therapy Recommendation



- **A. Löffler:** Antibiotic-resistance is a danger for man and animal. Responsible use is absolutely necessary
  - Perform cytology -> confirm the diagnosis
- **Identify and treat the primary disease**
- Systemic antibiotics with narrow spectrum as first line:
  - Amoxiclav (15-25 mg/kg 2x daily)
  - Cefalexin (20-30 mg/kg 2x daily)
  - Clindamycin (11 mg/kg once daily or 5mg/kg 2x tgl.)
- Shampoo, local therapy is good, not always possible...


Fizbo - tablet



later


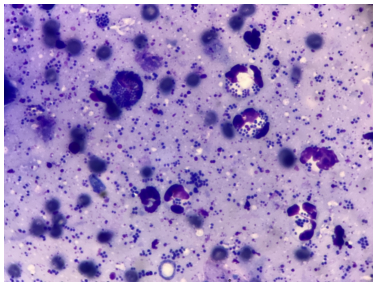






## Feline Pyoderma: do allergic cats need antibiotics?

- Very good evidence, that diverse allergy lesions are secondarily infected
- Little, but good quality evidence that Abx can help

## Feline Pyoderma: do allergic cats need antibiotics?

- Indirect evidence, that treating the primary disease, without treating the pyoderma, is often effective
  - Mueller RS, et al. Treatment of the feline atopic syndrome - a systematic review. Vet Dermatol. 2021
    - „Systemic glucocorticoids are rapid and effective in most cats with FASS“
    - „Based on the available evidence in a large number of cats with FASS, ciclosporin at a dose of 7 mg/kg once daily is efficacious in the treatment of reaction patterns caused by FASS“

## Feline Pyoderma: do allergic cats need antibiotics?

- Best chance for success (probably):
  - Treat both the primary disease and pyoderma parallel
  - But the decision is multifactorial...
    - Severity of the Pyoderma (cytology, clinical)
    - How many medications can the owner give? Budget?
    - Tolerance of antibiotic? (Antibiotic Associated Gastrointestinal Signs: AAGS)
      - Can be chronic!
    - TÄHAV in Germany – FQ, Cefovecin
- **Case by case decision**
  - When, then C & S is ideal (critical??- depends on case & therapy)



## Discussion/Questions?

